

REVIEW ARTICLE

MECHANISMS OF DISEASE

Parvovirus B19

Neal S. Young, M.D., and Kevin E. Brown, M.D.

From the Hematology Branch, National Heart, Lung, and Blood Institute, Bethesda, Md. Address reprint requests to Dr. Young at Bldg. 10, Rm. 7C103, National Institutes of Health, 9000 Rockville Pike, Bethesda, MD 20892-1652, or at youngn@nhlbi.nih.gov.

N Engl J Med 2004;350:586-97.

Copyright © 2004 Massachusetts Medical Society.

YVONNE COSSART, AN AUSTRALIAN VIROLOGIST WORKING IN LONDON in the mid-1970s, noted an anomalous reaction of a normal blood donor's serum (occupying position 19 in plate B) in an assay for hepatitis B. When Cossart excised the line of antigen-antibody precipitation, she saw the particles shown in Figure 1A, and in this way discovered a parvovirus in human blood.¹ With the same technique, antibodies to parvovirus B19 were found in a large proportion of normal adults, indicating that infection is common and probably occurs in childhood. A disease was linked to parvovirus B19 infection by John Pattison and colleagues, who found either virus-specific antibodies or the virus itself in samples from children who had a severe complication of sickle cell disease called transient aplastic crisis.² The most common illness caused by parvovirus B19 was identified a few years later, during outbreaks in the United Kingdom of fifth disease, a highly contagious childhood exanthem long suspected of having a viral cause.³ The virus has also been implicated in several other diseases^{4,5} (Table 1), and much has been discovered about how the virus causes these disorders. Diagnostic tests for the virus are commercially available, effective treatments are feasible, and a protective vaccine is under development.⁶⁻⁸

PARVOVIRUS B19 AND THE PARVOVIRIDAE

THE PARVOVIRUS FAMILY

The large Parvoviridae family includes many pathogenic animal viruses that have long been of interest to veterinarians and virologists. These viruses include feline panleukopenia virus,⁹ canine parvovirus,¹⁰ Aleutian mink disease virus,¹¹ and porcine parvovirus.¹² Adenoassociated viruses, also members of the Parvoviridae family, appear to infect humans without causing clinical manifestations and have been used as vectors for gene transduction and gene therapy.¹³

The parvoviruses are dependent on help from host cells or other viruses to replicate. The autonomous parvoviruses propagate in actively dividing cells, whereas the adenoassociated viruses grow in tissue cultures infected with adenoviruses and herpesviruses. Parvovirus B19 is the type member of the erythrovirus genus, which includes similar simian viruses,¹⁴ all of which propagate best in erythroid progenitor cells.

GENOME, TRANSCRIPTION, AND PROTEINS OF PARVOVIRUS B19

The parvoviruses are broadly defined by their size (the name comes from *parvum*, the Latin word for small): they form small capsids, about 25 nm in diameter (Fig. 1A), and contain a genome consisting of single-stranded DNA.^{15,16} The approximately 5600 nucleotides in the genome of parvovirus B19¹⁷ show remarkably few differences among isolates, with the exception of the sequences of two variants, V9 and A6,^{18,19} which are of uncertain clinical significance. Replication of a parvovirus entails double-stranded intermediate forms, which can be detected in tissue culture and clinical specimens by simple methods of DNA hybridization.

The transcription map of B19 and the other erythroviruses differs markedly from

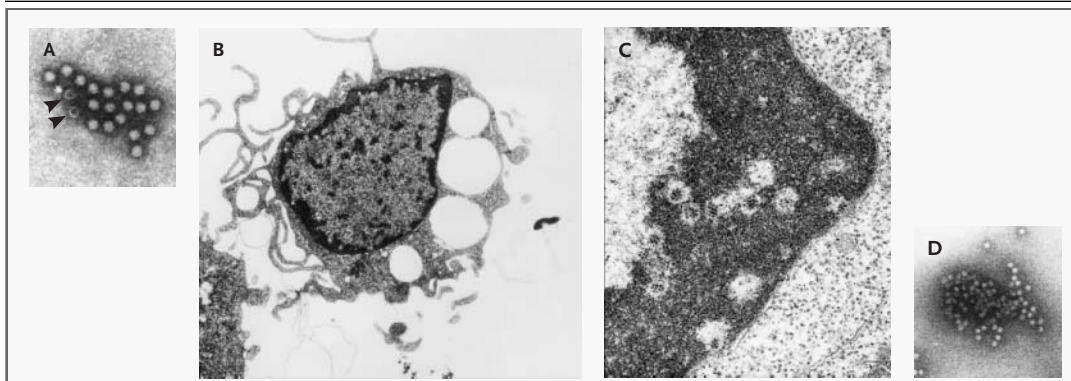


Figure 1. Transmission Electron Micrographs Showing Native Parvovirus B19 in Serum and Cells and Recombinant Capsids.

Panel A shows symmetric, icosahedral particles, about 25 nm in diameter, and empty capsids (arrowheads) in serum from an infected person (courtesy of Dr. Y. Cossart, $\times 189,000$). Panel B shows human erythroid progenitor cells infected in vitro with the virus; vacuoles and cytoplasmic pseudopods are present ($\times 10,000$). In Panel C, which shows part of Panel B at higher magnification, margined chromatin contains assembled capsids ($\times 100,000$). Panel D shows empty recombinant parvovirus capsids produced in a baculovirus system ($\times 154,000$).

that of other Parvoviridae, particularly in the use of a single promoter. The viral genome encodes only three proteins of known function (Fig. 2A). The nonstructural protein, from NS1, subserves multiple replicative functions and is cytotoxic to host cells.^{22,23} The two structural proteins, viral protein 1 (VP1) and viral protein 2 (VP2), arise from alternative splicing, so that VP1 is the same as VP2 except for an additional 226 amino acids at its amino terminal. The viral capsid of 60 capsomeres contains mainly VP2; VP1 accounts for only about 5 percent of the capsid protein. Folding of the proteins creates α -helical loops that appear on the surface of the assembled capsids, where the host's immune system can recognize them as antigenic determinants (Fig. 2B and 2C). The region unique to VP1 is external to the capsid itself and contains many linear epitopes recognized by neutralizing antibodies. (Epitopes are the parts of a molecule that are antigenic determinants.)

PARVOVIRUS B19 DISEASES

EPIDEMIOLOGY

Infection with parvovirus B19 is global; infectivity rates, inferred from the presence of antiparvovirus IgG antibody in serum samples, are similar in the United States, Europe, and Asia. Some isolated Amazonian tribes and populations of remote islands off

the coast of Africa have escaped exposure.^{24,25} Parvovirus B19 infection is common in childhood; half of 15-year-old adolescents have specific antiparvovirus B19 antibodies.²⁶ Infection continues at a lower rate throughout adult life, and by the time they are elderly, most persons are seropositive. In temperate climates, infections usually occur in the spring, and small epidemics at intervals of a few years are typical.²⁷ The virus is spread by respiratory droplets, and secondary infection rates among household contacts are very high.²⁸ Nosocomial infection has been described.²⁹ Parvovirus B19 has also been transmitted by blood products, especially pooled factor VIII and factor IX concentrates.³⁰ The absence of a lipid envelope and their genomic stability make parvoviruses notoriously resistant to heat inactivation and solvent detergents. Since January 2002, major producers of plasma derivatives have voluntarily instituted quantitative measurements of B19 DNA to reduce the risk of iatrogenic transmission.³¹

FIFTH DISEASE

Most cases of parvovirus B19 infection are asymptomatic.³² The most common clinical presentation of infection is erythema infectiosum, or fifth disease, a childhood exanthem characterized by a "slapped cheek" rash (Fig. 3A). Fifth disease takes its name from a list of common childhood exanthems, named in the order of the dates when they were first

Table 1. Major Diseases Caused by Parvovirus B19.

Disease	Acute or Chronic	Host
Fifth disease	Acute	Normal children
Arthropathy	Acute or chronic	Normal adults
Transient aplastic crisis	Acute	Patients with increased erythropoiesis
Persistent anemia	Chronic	Immunodeficient and immunocompromised patients
Hydrops fetalis and congenital anemia	Acute or chronic	Fetus

reported: measles, scarlet fever, rubella, Duke's (or fourth) disease, fifth disease, and roseola, or sixth disease. (Most pediatricians question the validity of fourth disease.) Intranasal inoculation of normal volunteers has produced fifth disease, and the experimental setting allowed detailed correlation of clinical manifestations with virologic and immunologic events³³ (Fig. 4A). Fever and nonspecific influenza-like symptoms occurred early, during the phase of parvoviremia. The later onset of a cutaneous eruption and rheumatic symptoms, about two weeks after the initial infection, corresponded to the appearance of antiviral antibodies. It is likely that these symptoms of parvovirus B19 infection are due to the formation and deposition of immune complexes in the skin and elsewhere. Serologic testing at this stage of infection generally shows seroconversion, IgM antibodies, or the new presence of IgG antibodies to parvovirus. The rash associated with fifth disease (Fig. 3A) may be evanescent, and recurrences can be provoked by exposure to sunlight, heat, emotion, or exercise. Fifth disease can be confused with rubella. In adults, the rash is less characteristic and may be difficult to see in persons with dark skin.

ARTHROPATHY

In contrast to the mild course of the rash illness in children with parvovirus B19 infection, in adults, particularly middle-aged women, the infection may cause clinically significant arthropathy.³⁵⁻³⁷ Not only arthralgia but also inflammatory arthritis occur in about 50 percent of older patients; approximately 15 percent of new cases of arthritis may represent the sequelae of parvovirus B19 infection.^{38,39} Symmetric joint involvement, usually of the hands and occasionally of the ankles, knees, and wrists, can mimic rheumatoid arthritis, and the results of a test for rheumatoid factor may be positive. However, ar-

thropathy associated with parvovirus B19 usually resolves within a few weeks, and even when symptoms persist for months or years, joint destruction does not occur. As in the case of the skin lesions of fifth disease, the pathogenesis of parvovirus B19 arthropathy is assumed to involve deposition of immune complexes.

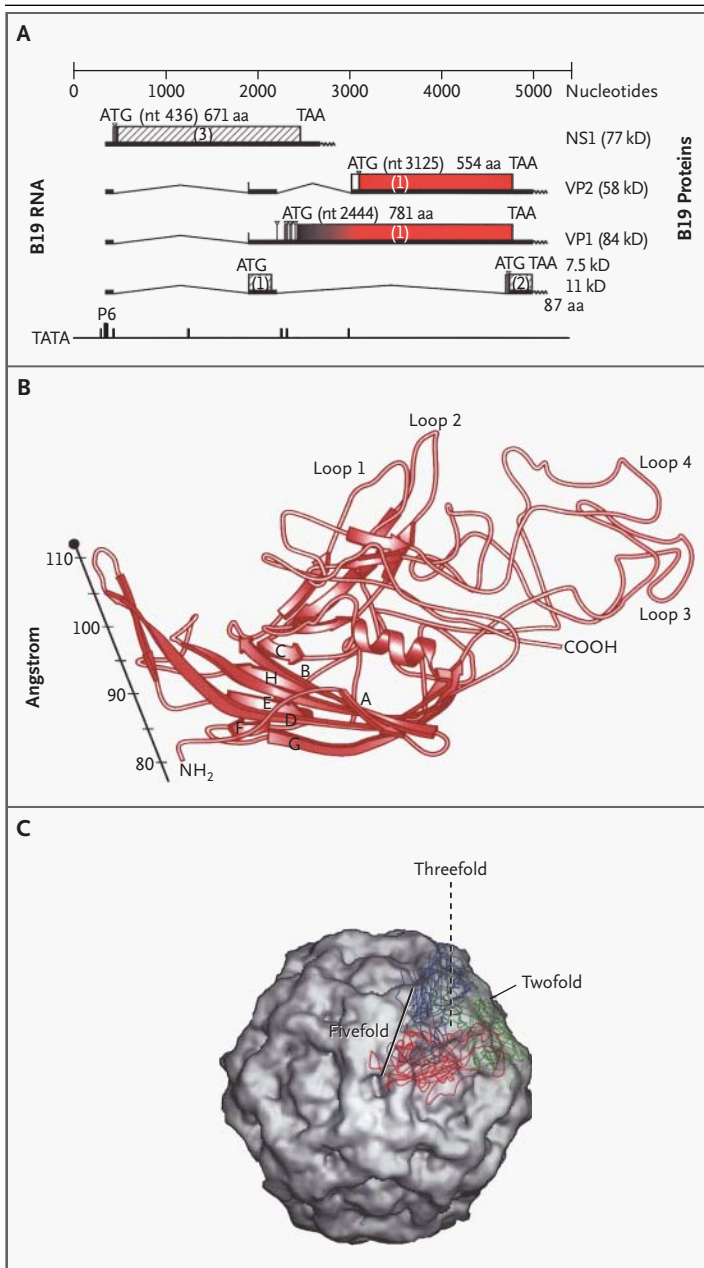
A role of parvovirus B19 in rheumatoid arthritis has not been proved. Patients with rheumatoid arthritis are not more likely to be seropositive for parvovirus B19 than are controls⁴⁰; conversely, B19 arthropathy does not progress to rheumatoid arthritis.⁴¹ Parvovirus B19 DNA may be present in inflamed joints but is also found in an equivalent proportion of control samples of synovial tissue.^{42,43} A report of the ubiquitous presence of parvovirus B19 in synovial tissue in cases of rheumatoid arthritis⁴⁴ has not been reproducible (unpublished data). Case reports suggest that parvovirus infection may mimic, precipitate, or exacerbate juvenile rheumatoid arthritis,^{45,46} systemic lupus erythematosus,⁴⁷ and fibromyalgia.⁴⁸ Antibodies against parvovirus B19 and parvovirus B19 DNA have been detected in blood samples from adults and children with rheumatic symptoms and antiphospholipid antibodies.⁴⁹

TRANSIENT APLASTIC CRISIS

In patients with increased destruction of red cells and a high demand for the production of erythrocytes, acute parvovirus B19 infection can cause an abrupt cessation of red-cell production, which exacerbates or, in compensated states, provokes severe anemia. Erythropoiesis is probably temporarily suppressed in all parvovirus B19 infections, since reticulocyte counts in normal volunteers fall to zero, but hemoglobin levels ordinarily remain stable because the erythrocyte has a long life span.³³ Anemic crises in hereditary spherocytosis and in sickle cell disease have long been recognized, and their simultaneous or sequential occurrence in families led to the suspicion of an infectious cause. In retrospect, regenerative acute anemias ascribed to kwashiorkor, vitamin deficiency, bacterial infections, some medical drugs, and even glue sniffing⁵⁰ were probably due to parvovirus infection. Examination of serially collected serum samples from a cohort of Jamaican patients with sickle cell anemia showed that virtually all cases of transient aplastic crises were related to recent parvovirus infection.^{51,52} Although patients with fifth disease typically have only antibodies against parvovirus and do not have viremia on

Figure 2. Molecular and Structural Features of Parvovirus B19.

Panel A shows a transcription map of the major genes and resulting transcripts. The nonstructural protein NS1 arises from the single unspliced transcript on the left-hand side of the genome (hatched areas). The capsid proteins VP1 and VP2 are encoded by genes with overlapping reading frames from the right-hand side of the genome (for simplicity, alternative splice messenger RNAs are not shown); aa denotes amino acids, nt nucleotides, (1), (2), and (3) reading frames, and P6, the single viral promoter. The capsid protein gene (Panel A), protein (Panel B), and placement of the protein in the capsid (Panel C) are shown in red. Panel B shows a ribbon diagram of a major capsid protein, adapted from Tsao et al.²⁰ Like many other viruses, parvovirus B19 VP2 has a determined secondary structure, with eight antiparallel β -pleated sheets (labeled A through H) forming a compact “jelly-roll” core and α -helical loops extending to the surface of the virus. COOH denotes the carboxy terminal, and NH₂ the amino terminal. In Panel C, cryo-electron microscopy²³ shows the surface topography of a parvovirus B19 particle, with superimposed positions of three identical capsid proteins and the two-, three-, and fivefold geometric axes of symmetry. The dashed and solid lines represent symmetric planes around a given point.



clinical presentation, viremia is present in transient aplastic crisis, and red-cell production resumes after antiviral antibodies that clear the infection have been produced (Fig. 4B).

Transient aplastic crisis is usually a unique event in the life of a patient, suggesting the induction of long-lasting, protective immunity. Although self-limited, an aplastic crisis can cause severe, occasionally fatal, anemia that precipitates congestive heart failure, cerebrovascular accidents, and acute splenic sequestration.⁵³ The bone marrow in patients with transient aplastic crisis is characterized by an absence of maturing erythroid precursors and the presence of giant pronormoblasts (Fig. 3B); these pathognomonic cells result from the cytopathic effect of parvovirus.

White-cell and platelet counts may fall somewhat during transient aplastic crisis, especially in patients with functioning spleens.⁵⁴ Occasional cases of agranulocytosis^{55,56} may be due to parvovirus B19, but evidence of the virus is infrequent in children with chronic neutropenia.⁵⁷ Thrombocytopenia and pancytopenia have been reported in patients with well-documented acute parvovirus infection.^{58,59} Parvovirus B19 can precipitate the hemophagocytic syndrome, usually with a favorable outcome.⁶⁰⁻⁶²

PERSISTENT PARVOVIRUS INFECTION

A lack of protective antibodies allows parvovirus B19 to persist (Fig. 4C). In the absence of antiviral immunity, fifth disease does not develop (because antigen-antibody complexes are not formed), but pure red-cell aplasia can be a manifestation of persistent B19 infection. The anemia is severe and requires transfusion; reticulocytes are absent from the blood, as are erythroid precursors from the marrow; giant pronormoblasts in a congruous clinical setting may

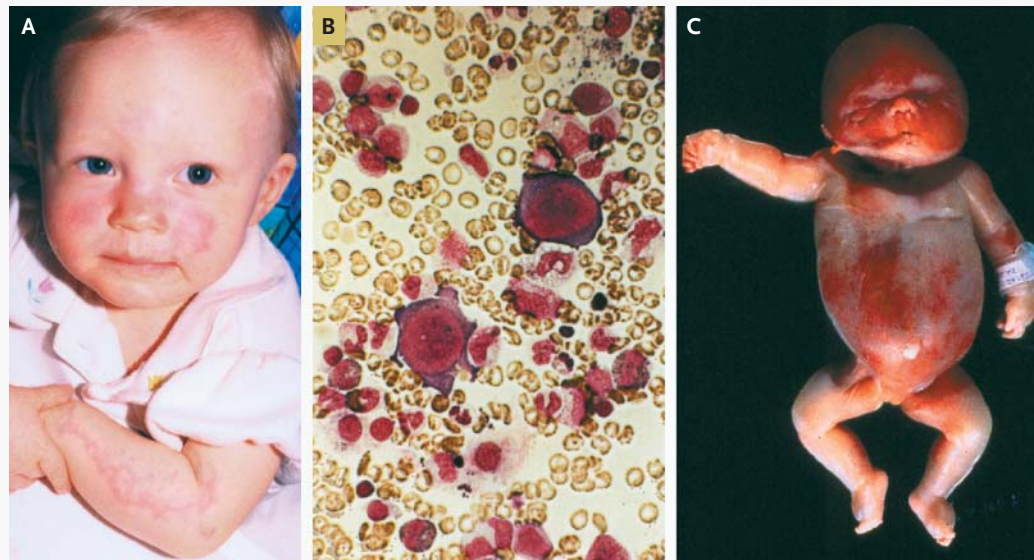


Figure 3. Clinical Manifestations of Parvovirus B19 Infection.

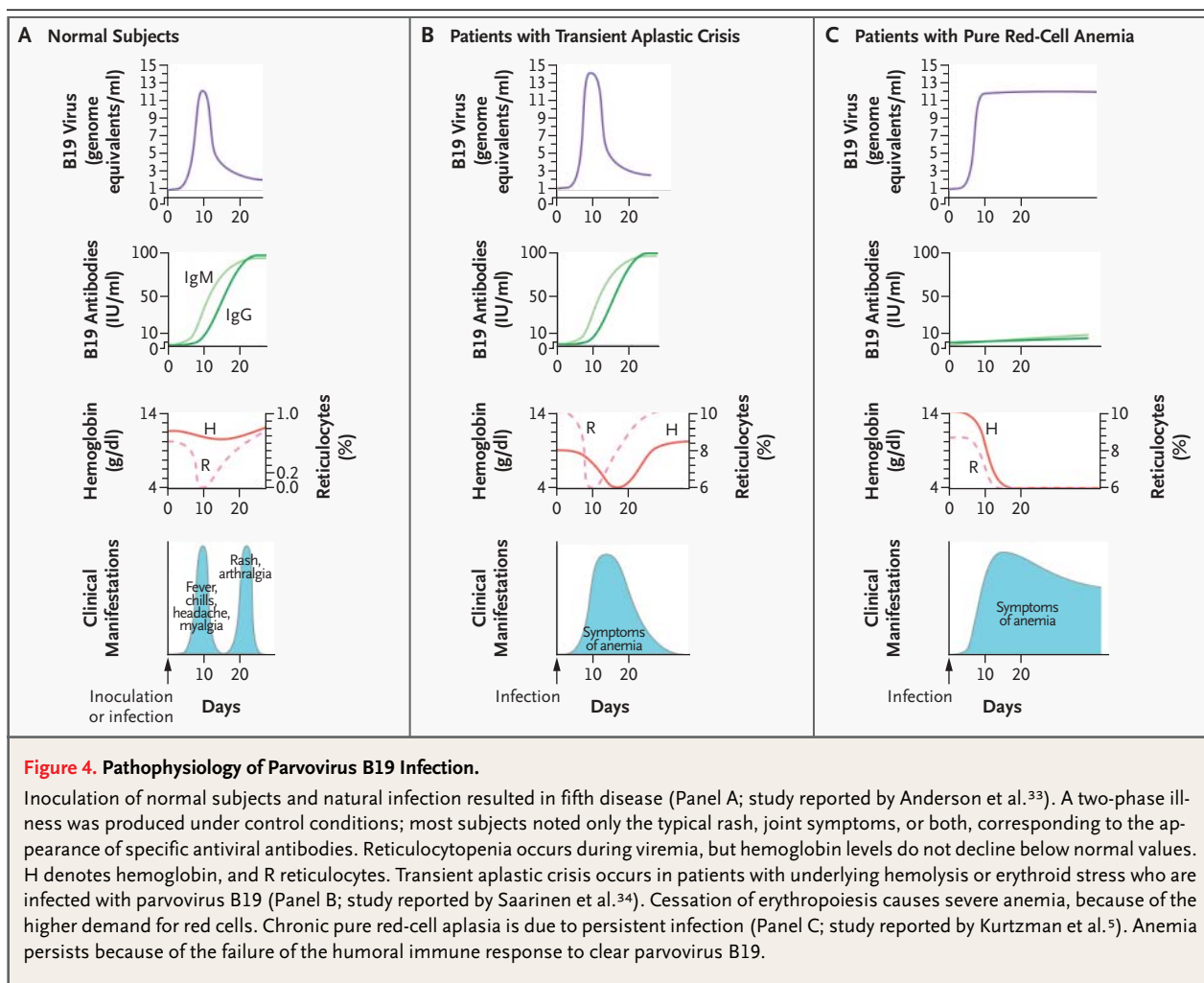
Panel A shows typical cutaneous eruptions in fifth disease, including “slapped” cheeks in children and a more generalized lacy, reticular pattern of erythema. Panel B shows a bone marrow aspirate with no mature erythroid precursors and with characteristic giant pronormoblasts. In Panel C, hydrops fetalis is evident in an infant who was infected in utero in midtrimester (courtesy of Dr. O. Caul).

lead to the diagnosis. Antibodies to parvovirus are usually absent; however, the virus can be readily detected in the circulation, often at extremely high levels ($>10^{12}$ genome copies per milliliter).

Failure to produce neutralizing antibodies to parvovirus B19 occurs in immunodeficiency states with congenital, iatrogenic, or infectious causes. The first patient in whom persistent parvovirus B19 infection was reported had the Nezelof syndrome, an inherited combined immunodeficiency disorder, in which susceptibility to parvovirus was the principal manifestation⁵; the simultaneous onset of apparently acquired pure red-cell aplasia in the patient and his brother was highly unusual. Red-cell aplasia due to persistent parvovirus infection has been reported in patients receiving cytotoxic chemotherapy or immunosuppressive drugs, often after organ transplantation.^{63,64} Pure red-cell aplasia due to parvovirus B19 also occurs in the acquired immunodeficiency syndrome (AIDS), sometimes as the first manifestation of infection with the human immunodeficiency virus (HIV).⁶⁵ Among HIV-positive men with anemia, persistent parvovirus B19 infection was a leading diagnostic possibility⁶⁶ (at least in the era before highly active antiretroviral therapy).

HYDROPS FETALIS

Parvovirus B19 infection in a pregnant woman, followed by transplacental transmission to the fetus, can lead to miscarriage or hydrops fetalis^{67,68} (Fig. 3C). Parvovirus infects the fetal liver, the site of erythrocyte production during early development. The swollen appearance in hydrops is the result of severe anemia and perhaps also myocarditis, both of which contribute to congestive heart failure.⁶⁹ Thrombocytopenia may accompany severe anemia.⁷⁰ Seroprevalence data indicate that about half of pregnant women are susceptible to parvovirus infection. On the basis of prospective studies in the United Kingdom⁷¹ and the United States,⁷² the estimated risk of transplacental infection among women who are infected with parvovirus B19 during pregnancy is 30 percent, with a 5 to 9 percent risk of fetal loss. Infection during the second trimester poses the greatest risk of hydrops fetalis. Parvovirus B19 probably accounts for 10 to 20 percent of all cases of nonimmune hydrops fetalis.⁷³ Approximately 8 percent of intrauterine fetal deaths were blamed on parvovirus B19 in a Swedish survey.⁷⁴ The risk of infection is highest in epidemic years and is correlated with the ex-



tent of contact the pregnant woman had with children.⁷⁵

Most parvovirus B19 infections during pregnancy do not lead to loss of the fetus. The few reported cases of developmental anomalies in the eyes or nervous system of infants with in utero exposure may be coincidental. However, severe anemia at birth with bone marrow morphologic features that are consistent with constitutional pure red-cell aplasia (Diamond-Blackfan anemia) or congenital dyserythropoietic anemia may be due to transplacental transmission of parvovirus B19 infection.⁷⁶

OTHER SUSPECTED PARVOVIRUS B19 SYNDROMES
Some skepticism about case reports of illnesses associated with parvovirus B19 is warranted, because systematic studies that include controls have often failed to validate these reports.⁷⁷ Frequently, the di-

agnosis of infection rests on detection of the B19 genome with the use of a polymerase-chain-reaction assay, but the notorious difficulty of ridding a laboratory of a highly stable contaminant that results from DNA amplification increases the rate of false positive results. Furthermore, parvovirus B19 can persist at low levels in the marrow,⁷⁸ joints,⁴³ and liver⁷⁹ of normal persons for many months after infection, confounding the meaning of a single positive test.

Elevated levels of hepatic aminotransferases can accompany fifth disease, and parvovirus infection has been associated with severe but self-limited hepatitis in a few children.⁸⁰ However, parvovirus B19 could not be implicated in larger numbers of patients with acute seronegative (non-A-E) hepatitis^{81,82} or chronic hepatitis.⁸³ Parvovirus B19 has been postulated to cause fulminant hepatitis,⁸⁴ but

we found no specific association.⁷⁹ The presence of genetic sequences of B19 in cardiac tissue has led to the diagnosis of parvovirus myocarditis,⁸⁵ myocarditis⁸⁶ and heart failure^{87,88} have followed fifth disease, and in one patient, chronic myocarditis was accompanied by persistent parvovirus B19 in the circulation.⁸⁸ In some series, an association between parvovirus infection and myocarditis was rare,⁸⁹ but in others, a high proportion of biopsy specimens from patients with inflamed hearts contained B19 DNA.⁹⁰

Serologic and DNA evidence of parvovirus B19 infection has been reported in some patients with necrotizing vasculitis,⁹¹ Kawasaki's disease,⁹² Henoch-Schönlein purpura,⁹³ or giant-cell arteritis.⁹⁴ The gloves-and-socks syndrome, an exanthem localized to the hands and feet, with edema, erythema, paresthesia, and pruritus, has also been linked to parvovirus B19.⁹⁵ The chronic fatigue syndrome may follow infection with parvovirus B19.^{96,97} Meningitis, encephalitis, and a variety of neurologic complications may occur with fifth disease and parvovirus infection.⁹⁸ Type 1 cytokines, tumor necrosis factor, and interferon- γ have all been associated with symptomatic parvovirus infection in patients with these syndromes.^{98,99}

PATHOPHYSIOLOGY

PARVOVIRUS B19 TROPISM

The only known natural host cell of parvovirus B19 is the human erythroid progenitor. This extraordinary tropism was first demonstrated in tissue culture, where small amounts of parvovirus B19 dramatically inhibited colony formation by early and especially by late erythroid progenitors without affecting myeloid colony formation.¹⁰⁰ In normal subjects who are experimentally inoculated with parvovirus B19, the numbers of erythroid progenitors in their bone marrow decline within a few days.¹⁰¹ Erythroid progenitors in cultures of bone marrow,¹⁰² peripheral blood,¹⁰³ and fetal liver¹⁰⁴ allow the propagation of parvovirus B19. A distinctive cytopathic effect and assembled parvovirus particles can be seen in isolated erythroid precursors from these cultures (Fig. 1B and 1C).

Globoside, a neutral glycolipid that acts as a cellular receptor,¹⁰⁵ accounts for the tropism of the virus for erythroid cells. The presence of globoside in the placenta and in fetal myocardium — mainly on the surface of erythroid precursors and red cells but also on some megakaryocytes and endothelial

cells — is consistent with the clinical effects of parvovirus B19 infection. Globoside is also known as erythrocyte P antigen. Rare persons of the p phenotype blood group, whose erythrocytes lack P antigen, are not susceptible to infection with parvovirus B19; they have no serologic evidence of prior infection, and their marrow erythroid progenitors proliferate normally in the presence of high concentrations of virus.¹⁰⁶ The nonstructural protein of parvovirus is responsible for the death of erythroid progenitors, and some cells, such as megakaryocytes, may be lysed by restricted expression of viral proteins in the absence of viral propagation.¹⁰⁷

The simian parvoviruses, which cause outbreaks of severe anemia in caged animals, similarly target erythroid cells¹⁰⁸; experimental infection of monkeys results in conditions that mimic human pure red-cell aplasia and hydrops fetalis.¹⁰⁹ Other parvoviruses that target hematopoietic cells more broadly are the feline panleukopenia virus¹¹⁰ and the minute virus of mice.¹¹¹

IMMUNITY TO PARVOVIRUS B19

The antibody response is dominant in parvovirus B19 infection (indeed, it has been difficult to demonstrate a T-cell response to the parvovirus). Antibody production is correlated with the disappearance of virus from the blood, and IgG antibodies appear to confer lasting protection against reinfection. The basis of persistent parvovirus infection is a defect in immunoglobulin production. Serum from patients with persistent infection lacks antibodies to parvovirus B19 or contains low levels of nonneutralizing IgM or IgG antibodies.¹¹² Antibodies to the unique amino-terminal region of VP1 are important for clearance of the virus. Serum samples from patients in the early phase of convalescence react to VP2, but serum samples from patients in the late phase (and commercial immunoglobulins derived from the plasma of normal subjects) have strong anti-VP1 activity. Experiments with recombinant capsids, in which VP2 or VP2 plus VP1 assembled in the empty capsids¹¹³ (Fig. 1D), demonstrated the crucial role VP1 has in the immune response. Capsids containing VP2 only and those containing VP2 plus VP1 differ markedly in their ability to elicit a neutralizing immune response in both animals¹¹³ and humans.¹¹⁴ VP1 is required for an effective immune response, whereas VP2 is ineffective.^{115,116} The function of VP1 is not known, but its phospholipase activity¹¹⁷ suggests that it has a role in viral entry into cells. Peptides derived from VP2 may be

pathogenic in parvovirus B19 arthropathy, since they can induce cross-reactive autoantibodies against human keratin, collagen, and cardiolipin.¹¹⁸

CLINICAL DIAGNOSIS

Laboratory diagnosis of parvovirus B19 infection relies on serologic and DNA tests, because propagating the virus in standard tissue culture is difficult^{119,120} (Table 2). Virus-specific antibodies are measured in standardized commercial solid-phase, enzyme-labeled immunoassays, usually with the use of recombinant capsid proteins. IgM antibodies are detected in almost all cases of fifth disease at the time of presentation, and they appear within a few days after the onset of transient aplastic crisis; these antibodies persist for two to three months after acute infection. Substantial interindividual variation and the presence of IgG antibodies in a large proportion of the population make measurement of IgG less helpful than other tests for the diagnosis of parvovirus B19 infection. DNA assays are required to diagnose persistent infection, since antibody production is absent or minimal. Parvovirus DNA can also be found in serum early in the course of a transient aplastic crisis. Direct hybridization methods are reliable and can detect clinically relevant viral titers of more than 10^6 genome copies. Gene-amplification methods are more sensitive, but the results may be false positive because of contamination or uninterpretable because low levels of virus may persist for months or years after an acute infection in a normal person. Virus can be detected in amniotic fluid, and both virus and IgM antibodies to parvovirus B19 are detectable in umbilical-cord blood¹²²; maternal serum will show seroconversion during pregnancy, but tests for maternal IgM antibodies may be negative at the onset of hydrops fetalis.

TREATMENT AND PREVENTION

SPECIFIC THERAPIES

Most cases of parvovirus infection in children and adults do not require specific therapy. Isolation of infected persons is impractical, with the exception of hospitalized patients. Pure red-cell aplasia and the underlying persistent parvovirus B19 infection may be terminated rapidly by discontinuing immunosuppressive therapy, or by instituting antiretroviral drug therapy in patients with AIDS. Commercial immune globulins are a good source of

Table 2. Results of Diagnostic Assays for Diseases Caused by Parvovirus B19.*

Disease	IgM	IgG	B19 DNA Hybridization	B19 DNA Amplification
Fifth disease	+++	++	-	+
Arthropathy	++	+	-	+
Transient aplastic crisis	+/-	+/-	++	++
Persistent anemia	+/-	+/-	++	++
Hydrops fetalis and congenital infection	+/-	+	+/-	++
Previous infection	-	++	-	+/-

* The sensitivity of direct DNA hybridization methods is approximately 10^6 genome copies per milliliter, and the sensitivity of DNA amplification techniques (polymerase chain reaction) is approximately 10^2 genome copies per milliliter.^{118,121} Plus signs and minus signs denote positive and negative results, respectively, and greater numbers of plus signs indicate stronger positive results.

antibodies against parvovirus; a persistent B19 infection responds to a 5- or 10-day course of immune globulin at a dose of 0.4 g per kilogram of body weight, with a prompt decline in serum viral DNA, as measured by hybridization methods, accompanied by reticulocytosis and increased hemoglobin levels.^{5,65} This regimen has been curative in patients with congenital immunodeficiency, but in patients with AIDS, parvovirus often persists at lower levels, detectable by gene-amplification methods; relapses of anemia may require repeated administration of immune globulin. Immune globulin therapy can precipitate the rash and joint symptoms of fifth disease. Hydrops fetalis may resolve spontaneously, but intrauterine blood transfusions have been used with apparent success.^{70,123-125} Chronic arthropathy has been treated symptomatically with antiinflammatory drugs. The benefit of immune globulin therapy is less clear in syndromes in which the virus does not circulate.

Avoiding both the misinterpretation of laboratory results — such as positive tests for IgG antibodies or borderline results of IgM and DNA tests — and the use of misguided therapies is as important as recognizing parvovirus infection. The administration of immune globulin in a patient with fulminant hepatitis or aplastic anemia not only is costly but can also delay an appropriate treatment, such as hepatic or hematopoietic stem-cell transplantation.

VACCINE DEVELOPMENT

Effective vaccines are available for animal parvoviruses, and it is likely that parvovirus B19 infection

can also be prevented. The recombinant immunogen that is being developed as a vaccine for the human virus lacks DNA and is therefore noninfectious; empty capsids have been engineered to overexpress the highly immunogenic VP1, and a single dose of 2.5 μ g of empty capsids elicited neutralizing antibody responses in normal volunteers.¹¹⁴ As with many other vaccines, commercial interest rather than lack of efficacy or safety has limited the development of a parvovirus B19 vaccine. Such a vaccine could prevent transient aplastic crisis in patients with sickle cell disease or other hemolytic anemias and pure red-cell aplasia in some immunodeficient persons, as well as hydrops fetalis, if seronegative women were inoculated early in pregnancy.

Chimeric viral capsids have been proposed as more general vehicles for the delivery of antigens, and parvovirus B19 is especially attractive for this purpose, because the VP1 unique region can be entirely replaced with other protein sequences, allowing, for example, the presentation of a conformationally and functionally intact enzyme on the surface of the empty viral capsid.¹²⁶ This method is now being adapted for protection against an agent

of bioterrorism: a domain of protective antigen of anthrax is being incorporated on a parvovirus B19 particle.

CONCLUSIONS

Parvovirus B19 is an excellent example of the dependence of the clinical manifestations of disease on the intrinsic properties of a pathogen and the peculiarities of the infected host. Distinct B19 syndromes are prominent in pediatrics and obstetrics, dermatology, rheumatology, and hematology, but the full spectrum of virus-induced disease has not yet been defined. Symptoms and signs follow from the infected person's hematopoietic and immune status, and parvovirus infection can range from an asymptomatic condition to life-threatening disease. In the quarter century since Cossart's discovery, our knowledge of parvovirus B19 has led to the recognition of new human diseases, as well as the development of diagnostic assays, effective treatments, and a candidate vaccine.

We are indebted to M.G. Rossmann for his assistance with Figure 2C.

REFERENCES

- Cossart YE, Field AM, Cant B, Widdows D. Parvovirus-like particles in human sera. *Lancet* 1975;1:72-3.
- Pattison JR, Jones SE, Hodgson J, et al. Parvovirus infections and hypoplastic crisis in sickle cell anaemia. *Lancet* 1981;1:664-5.
- Anderson MJ, Lewis E, Kidd IM, Hall SM, Cohen BJ. An outbreak of erythema infectiosum associated with human parvovirus infection. *J Hyg (London)* 1984;93:85-93.
- Anand A, Gray ES, Brown T, Clewley JP, Cohen BJ. Human parvovirus infection in pregnancy and hydrops fetalis. *N Engl J Med* 1987;316:183-6.
- Kurtzman G, Frickhofen N, Kimball J, Jenkins DW, Nienhuis AW, Young NS. Pure red-cell aplasia of 10 years' duration due to persistent parvovirus B19 infection and its cure with immunoglobulin therapy. *N Engl J Med* 1989;321:519-23.
- Anderson LJ, Young NS, eds. Human parvovirus B19. Vol. 20 of *Monographs in virology*. Basel, Switzerland: Karger, 1997.
- Bloom ME, Young NS. Parvoviruses. In: Knipe DM, Howley PM, eds. *Fields virology*. Philadelphia: Lippincott Williams & Wilkins, 2001:2361-79.
- Heegaard ED, Brown KE. Human parvovirus B19. *Clin Microbiol Rev* 2002;15:485-505.
- Verge J, Cristoforoni N. La gastro-entérite infectieuse des chats est-elle due à un virus filtrable? *C R Soc Biol* 1928;99:312-4.
- Parrish CR. Pathogenesis of feline panleukopenia virus and canine parvovirus. *Baillieres Clin Haematol* 1995;8:57-71.
- Bloom ME, Kanno H, Mori S, Wolfinger JB. Aleutian mink disease: puzzles and paradigms. *Infect Agents Dis* 1994;3:279-301.
- Molitor TW, Joo HS. Clinical and pathological features of porcine-parvovirus-related disease and its diagnosis. In: Tijssen P, ed. *CRC handbook of parvoviruses*. Vol. 2. Boca Raton, Fla.: CRC Press, 1990:135-50.
- Muzyczka N, Berns KI. Parvoviridae: the viruses and their replication. In: Knipe DM, Howley PM, eds. *Fields virology*. Philadelphia: Lippincott Williams & Wilkins, 2001:2327-59.
- Brown KE, Young NS. The simian parvoviruses. *Rev Med Virol* 1997;7:211-8.
- Shade RO, Blundell MC, Cotmore SF, Tattersall P, Astell CR. Nucleotide sequence and genome organization of human parvovirus B19 isolated from the serum of a child during aplastic crisis. *J Virol* 1986;58:921-36.
- Fauquet CM, van Regenmortel MHV, Bishop DHL. *Virus taxonomy deluxe: classification and nomenclature of viruses: seventh report of the International Committee on Taxonomy of Viruses*. San Diego, Calif.: Academic Press, 2001.
- Cotmore SF, Tattersall P. Characterization and molecular cloning of a human parvovirus genome. *Science* 1984;226:1161-5.
- Nguyen QT, Sifer C, Schneider V, et al. Novel human erythrovirus associated with transient aplastic anemia. *J Clin Microbiol* 1999;37:2483-7.
- Nguyen QT, Wong S, Heegaard ED, Brown KE. Identification and characterization of a second novel human erythrovirus variant, A6. *Virology* 2002;301:374-80.
- Tsao J, Chapman MS, Agbandje M, et al. The three-dimensional structure of canine parvovirus and its functional implications. *Science* 1991;251:1456-64.
- Chipman PR, Agbandje-McKenna M, Kajigaya S, et al. Cryo-electron microscopy studies of empty capsids of human parvovirus B19 complexed with its cellular receptor. *Proc Natl Acad Sci U S A* 1996;93:7502-6.
- Ozawa K, Ayub J, Kajigaya S, Shimada T, Young NS. The gene encoding the nonstructural protein of B19 (human) parvovirus may be lethal in transfected cells. *J Virol* 1988;62:2884-9.
- Moffatt S, Yaegashi N, Tada K, Tanaka N, Sugamura K. Human parvovirus B19 nonstructural (NS1) protein induces apoptosis in erythroid lineage cells. *J Virol* 1998;72:3018-28.
- Schwarz TF, Gurtler LG, Zoulek G, Deinhardt F, Roggendorf M. Seroprevalence of human parvovirus B19 infection in Sao Tome and Principe, Malawi and Mascarene Islands. *Zentralbl Bakteriol* 1989;271:231-6.
- de Freitas RB, Wong D, Boswell F, et al. Prevalence of human parvovirus (B19) and rubella virus infections in urban and remote

- rural areas in northern Brazil. *J Med Virol* 1990;32:203-8.
26. Risks associated with human parvovirus B19 infection. *MMWR Morb Mortal Wkly Rep* 1989;38:81-8, 93-7.
 27. Human parvovirus B19 infections in United Kingdom 1984-86. *Lancet* 1987;1:738-9.
 28. Chorba TL, Coccia P, Holman RC, et al. The role of parvovirus B19 in aplastic crisis and erythema infectiosum (fifth disease). *J Infect Dis* 1986;154:383-93.
 29. Bell LM, Naides SJ, Stoffman P, Hodinka RL, Plotkin SA. Human parvovirus B19 infection among hospital staff members after contact with infected patients. *N Engl J Med* 1989;321:485-91.
 30. Azzi A, Morfini M, Mannucci PM. The transfusion-associated transmission of parvovirus B19. *Transfus Med Rev* 1999;13:194-204.
 31. Brown KE, Young NS, Alving BM, Barbosa LH. Parvovirus B19: implications for transfusion medicine: summary of a workshop. *Transfusion* 2001;41:130-5.
 32. Woolf AD, Campion GV, Chishick A, et al. Clinical manifestations of human parvovirus B19 in adults. *Arch Intern Med* 1989;149:1153-6.
 33. Anderson MJ, Higgins PG, Davis LR, et al. Experimental parvoviral infection in humans. *J Infect Dis* 1985;152:257-65.
 34. Saarinen UM, Chorba TL, Tattersall P, et al. Human parvovirus B19-induced epidemic acute red cell aplasia in patients with hereditary hemolytic anemia. *Blood* 1986;67:1411-7.
 35. Moore TL. Parvovirus-associated arthritis. *Curr Opin Rheumatol* 2000;12:289-94.
 36. Kerr JR. Pathogenesis of human parvovirus B19 in rheumatic disease. *Ann Rheum Dis* 2000;59:672-83.
 37. Naides SJ. Rheumatic manifestations of parvovirus B19 infection. *Rheum Dis Clin North Am* 1998;24:375-401.
 38. Reid DM, Reid TMS, Brown T, Rennie JAN, Eastmond CJ. Human parvovirus-associated arthritis: a clinical and laboratory description. *Lancet* 1985;1:422-5.
 39. White DG, Woolf AD, Mortimer PP, Cohen BJ, Blake DR, Bacon PA. Human parvovirus arthropathy. *Lancet* 1985;1:419-21.
 40. Nikkari S, Luukkainen R, Möttönen T, et al. Does parvovirus B19 have a role in rheumatoid arthritis? *Ann Rheum Dis* 1994;53:106-11.
 41. Speyer I, Breedveld FC, Dijkman BAC. Human parvovirus B19 infection is not followed by inflammatory joint disease during long term follow-up: a retrospective study of 54 patients. *Clin Exp Rheumatol* 1998;16:576-8.
 42. Kerr JR, Cartron JP, Curran MD, Moore JE, Elliott JRM, Mollan RAB. A study of the role of parvovirus B19 in rheumatoid arthritis. *Br J Rheumatol* 1995;34:809-13.
 43. Soderlund M, von Essen R, Haapasaaari J, Kiistala U, Kiviluoto O, Hedman K. Persistence of parvovirus B19 DNA in synovial membranes of young patients with and without chronic arthropathy. *Lancet* 1997;349:1063-5.
 44. Takahashi Y, Murai C, Shibata S, et al. Human parvovirus B19 as a causative agent for rheumatoid arthritis. *Proc Natl Acad Sci U S A* 1998;95:8227-32.
 45. Mimori A, Misaki Y, Hachiya T, Ito K, Kano S. Prevalence of antihuman parvovirus B19 IgG antibodies in patients with refractory rheumatoid arthritis and polyarticular juvenile rheumatoid arthritis. *Rheumatol Int* 1994;14:87-90.
 46. Lehmann HW, von Landenberg P, Modrow S. Parvovirus B19 infection and autoimmune disease. *Autoimmun Rev* 2003;2:218-23.
 47. Tanaka A, Sugawara A, Sawai K, Kuwahara T. Human parvovirus B19 infection resembling systemic lupus erythematosus. *Intern Med* 1998;37:708-10.
 48. Leventhal NJ, Naides SJ, Freundlich B. Fibromyalgia and parvovirus infection. *Arthritis Rheum* 1991;34:1319-24.
 49. Landenberg P, Lehmann HW, Knoll A, Dorsch S, Modrow S. Antiphospholipid antibodies in pediatric and adult patients with rheumatic disease are associated with parvovirus B19 infection. *Arthritis Rheum* 2003;48:1393-47.
 50. Powars D. Aplastic anemia secondary to glue sniffing. *N Engl J Med* 1965;273:700-2.
 51. Serjeant GR, Topley JM, Mason K, et al. Outbreak of aplastic crises in sickle cell anaemia associated with parvovirus-like agent. *Lancet* 1981;2:595-7.
 52. Serjeant BE, Hambleton RR, Kerr S, Kilty CG, Serjeant GR. Haematological response to parvovirus B19 infection in homozygous sickle-cell disease. *Lancet* 2001;358:1779-80.
 53. Smith-Whitley K, Zhao H, Hodinka RL, et al. Epidemiology of human parvovirus B19 in children with sickle cell disease. *Blood* 2004;103:422-7.
 54. Saunders PWG, Reid MM, Cohen BJ. Human parvovirus induced cytopenias: a report of five cases. *Br J Haematol* 1986;63:407-10.
 55. Pont J, Puchhammer-Stöckl E, Chott A, et al. Recurrent granulocytic aplasia as clinical presentation of a persistent parvovirus B19 infection. *Br J Haematol* 1992;80:160-5.
 56. Barlow GD, McKendrick MW. Parvovirus B19 causing leucopenia and neutropenia in a healthy adult. *J Infect* 2000;40:192-5.
 57. Bux J, Behrens G, Jaeger G, Welte K. Diagnosis and clinical course of autoimmune neutropenia in infancy: analysis of 240 cases. *Blood* 1998;91:181-6.
 58. Osaki M, Matsubara K, Iwasaki T, et al. Severe aplastic anemia associated with human parvovirus B19 infection in a patient without underlying disease. *Ann Hematol* 1999;78:83-6.
 59. Quian XH, Zhang GC, Jiao XY, et al. Aplastic anemia associated with parvovirus B19 infection. *Arch Dis Child* 2002;87:436-7.
 60. Koch WC, Massey G, Russell CE, Adler SP. Manifestations and treatment of human parvovirus B19 infection in immunocompromised patients. *J Pediatr* 1990;116:355-9.
 61. Hoang MP, Dawson DP, Rogers ZR, Scheuermann RH, Rogers BB. Polymerase chain reaction amplification of archival material for Epstein-Barr virus, cytomegalovirus, human herpesvirus 6, and parvovirus B19 in children with bone marrow hemophagocytosis. *Hum Pathol* 1998;29:1074-7.
 62. Shirono K, Tsuda H. Parvovirus B19-associated haemophagocytic syndrome in healthy adults. *Br J Haematol* 1995;89:923-6.
 63. Kurtzman G, Cohen B, Meyers P, Amunnullah A, Young NS. Persistent B19 parvovirus infection as a cause of severe chronic anaemia in children with acute lymphocytic leukaemia. *Lancet* 1988;2:1159-62.
 64. Heegaard ED, Schmiegelow K. Serologic study on parvovirus B19 infection in childhood acute lymphoblastic leukemia during chemotherapy: clinical and hematologic implications. *J Pediatr Hematol Oncol* 2002;24:368-73.
 65. Frickhofen N, Abkowitz J, Safford M, et al. Persistent parvovirus infection in patients infected with human immunodeficiency virus type 1 (HIV-1): a treatable cause of anemia in AIDS. *Ann Intern Med* 1990;113:926-33.
 66. Abkowitz JL, Brown KE, Wood RW, Kovach NL, Green SW, Young NS. Clinical relevance of parvovirus B19 as a cause of anemia in patients with human immunodeficiency virus infection. *J Infect Dis* 1997;176:269-73.
 67. Levy R, Weissman A, Blomberg G, Hagay ZJ. Infection by parvovirus B19 during pregnancy: a review. *Obstet Gynecol Surv* 1997;52:254-9.
 68. Alger LS. Toxoplasmosis and parvovirus B19. *Infect Dis Clin North Am* 1997;11:55-75.
 69. Morey AL, Keeling JW, Porter HJ, Fleming KA. Clinical and histopathological features of parvovirus B19 infection in the human fetus. *Br J Obstet Gynaecol* 1992;99:566-74.
 70. Forestier F, Tissot JD, Vial Y, Daffos F, Hohlfeld P. Haematological parameters of parvovirus B19 infection in 13 fetuses with hydrops foetalis. *Br J Haematol* 1999;104:925-7.
 71. Miller E, Fairley CK, Cohen BJ, Seng C. Immediate and long term outcome of human parvovirus B19 infection in pregnancy. *Br J Obstet Gynaecol* 1998;105:174-8.
 72. Rodis JF, Quinn DL, Gary GW Jr, et al. Management and outcomes of pregnancies complicated by human B19 parvovirus infection: a prospective study. *Am J Obstet Gynecol* 1990;163:1168-71.
 73. Jordan JA. Identification of human parvovirus B19 infection in idiopathic nonimmune hydrops fetalis. *Am J Obstet Gynecol* 1996;174:37-42.
 74. Skjoldbrand-Sparre L, Tolfvenstam T, Papadogiannakis N, Wahren B, Broliden K,

- Nyman M. Parvovirus B19 infection: association with third-trimester intrauterine fetal death. *BJOG* 2000;107:476-80.
75. Valeur-Jensen AK, Pedersen CB, Westergaard T, et al. Risk factors for parvovirus B19 infection in pregnancy. *JAMA* 1999;281:1099-105.
76. Brown KE, Green SW, Antunez de Mayolo J, et al. Congenital anemia after transplant B19 parvovirus infection. *Lancet* 1994;343:895-6.
77. Török TJ. Unusual clinical manifestations reported in patients with parvovirus B19 infection. In: Anderson LJ, Young NS, eds. *Human parvovirus B19*. Vol. 20 of *Monographs in virology*. Basel, Switzerland: Karger, 1997:61-92.
78. Cassinotti P, Siegl G, Michel BA, Brühlmann P. Presence and significance of human parvovirus B19 DNA in synovial membranes and bone marrow from patients with arthritis of unknown origin. *J Med Virol* 1998;56:199-204.
79. Wong S, Young NS, Brown KE. Prevalence of parvovirus B19 in liver tissue: no association with fulminant hepatitis or hepatitis-associated aplastic anemia. *J Infect Dis* 2003;187:1581-6.
80. Sokal EM, Melchior M, Cornu C, et al. Acute parvovirus B19 infection associated with fulminant hepatitis of favourable prognosis in young children. *Lancet* 1998;352:1739-41.
81. Notari EP, Orton SL, Cable RG, et al. Seroprevalence of known and putative hepatitis markers in United States blood donors with ALT levels at least 120 IU per L. *Transfusion* 2001;41:751-5.
82. He Z, Zhuang H, Wang X, et al. Retrospective analysis of non-A-E hepatitis: possible role of hepatitis B and C virus infection. *J Med Virol* 2003;69:59-65.
83. Arista S, De Grazia S, Di Marco V, Di Stefano R, Craxi A. Parvovirus B19 and "cryptogenic" chronic hepatitis. *J Hepatol* 2003;38:375-6.
84. Langnas AN, Markin RS, Cattral MS, Naides SJ. Parvovirus B19 as a possible causative agent of fulminant liver failure and associated aplastic anemia. *Hepatology* 1995;22:1661-5.
85. Dettmeyer R, Kandolf R, Baasner A, Banaschak S, Eis-Hubinger AM, Madea B. Fatal parvovirus B19 myocarditis in an 8-year-old boy. *J Forensic Sci* 2003;48:183-6.
86. Beghetti M, Gervais A, Haeggeli CA, Berner M, Rimensberger PC. Myocarditis associated with parvovirus B19 infection in two siblings with merosin-deficient congenital muscular dystrophy. *Eur J Pediatr* 2000;159:135-6.
87. Saint-Martin J, Choulot JJ, Bonnaud E, Morinet F. Myocarditis caused by parvovirus. *J Pediatr* 1990;116:1007-8.
88. Nigro G, Bastianon V, Colloridi V, et al. Human parvovirus B19 infection in infancy associated with acute and chronic lymphocytic myocarditis and high cytokine levels: report of 3 cases and review. *Clin Infect Dis* 2000;31:65-9.
89. Schowengerdt KO, Ni J, Denfield SW, et al. Association of parvovirus B19 genome in children with myocarditis and cardiac allograft rejection: diagnosis using the polymerase chain reaction. *Circulation* 1997;96:3549-54.
90. Pankuweit S, Moll R, Baandrup U, Portig I, Hufnagel G, Maisch B. Prevalence of the parvovirus B19 genome in endomyocardial biopsy specimens. *Hum Pathol* 2003;34:497-503. abstract.
91. Finkel TH, Török TJ, Ferguson PJ, et al. Chronic parvovirus B19 infection and systemic necrotising vasculitis: opportunistic infection or aetiological agent? *Lancet* 1994;343:1255-8.
92. Nigro G, Zerbini M, Krzysztowiak A, et al. Active or recent parvovirus B19 infection in children with Kawasaki disease. *Lancet* 1994;343:1260-1.
93. Ferguson PJ, Saulsbury FT, Dowell SF, Török TJ, Erdman DD, Anderson LJ. Prevalence of human parvovirus B19 infection in children with Henoch-Schönlein purpura. *Arthritis Rheum* 1996;39:880-1.
94. Gabriel SE, Espy M, Erdman DD, Bjornsson J, Smith TF, Hunder GG. The role of parvovirus B19 in the pathogenesis of giant cell arteritis: a preliminary evaluation. *Arthritis Rheum* 1999;42:1255-8.
95. Smith SB, Libow LF, Elston DM, Bernert RA, Warschaw KE. Gloves and socks syndrome: early and late histopathologic features. *J Am Acad Dermatol* 2002;47:749-54.
96. Jacobson SK, Daly JS, Thorne GM, McIntosh K. Clinical parvovirus B19 infection resulting in chronic fatigue syndrome: case history and review. *Clin Infect Dis* 1997;24:1048-51.
97. Kerr JR, Bracewell J, Laing I, et al. Chronic fatigue syndrome and arthralgia following parvovirus B19 infection. *Rheumatology* 2002;29:595-602.
98. Kerr JR, Barah E, Chiswick ML, et al. Evidence for the role of demyelination, HLA-DR alleles, and cytokines in the pathogenesis of parvovirus B19 meningoencephalitis and its sequelae. *J Neurol Neurosurg Psychiatry* 2002;73:739-46.
99. Barash J, Dushnitski D, Barak Y, Miron S, Hahn T. Tumor necrosis factor (TNF)alpha and its soluble receptor (sTNFR) p75 during acute human parvovirus B19 infection in children. *Immunol Lett* 2003;88:109-12.
100. Mortimer PP, Humphries RK, Moore JG, Purcell RH, Young NS. A human parvovirus-like virus inhibits haematopoietic colony formation in vitro. *Nature* 1983;302:426-9.
101. Potter CG, Potter AC, Hatton CSR, et al. Variation of erythroid and myeloid precursors in the marrow and peripheral blood of volunteer subjects infected with human parvovirus (B19). *J Clin Invest* 1987;79:1486-92.
102. Ozawa K, Kurtzman G, Young NS. Replication of the B19 parvovirus in human bone marrow cell cultures. *Science* 1986;233:883-6.
103. Serke S, Schwarz TF, Baurmann H, et al. Productive infection of in vitro generated haematopoietic progenitor cells from normal human adult peripheral blood with parvovirus B19: studies by morphology, immunocytochemistry, flow-cytometry, and DNA-hybridization. *Br J Haematol* 1991;79:6-13.
104. Yaegashi N, Shiraishi H, Takeshita T, Nakamura M, Yajima A, Sugamura K. Propagation of human parvovirus B19 in primary culture of erythroid lineage cells derived from fetal liver. *J Virol* 1989;63:2422-6.
105. Brown KE, Anderson SM, Young NS. Erythrocyte P antigen: cellular receptor for B19 parvovirus. *Science* 1993;262:114-7.
106. Brown KE, Hibbs JR, Gallinella G, et al. Resistance to human parvovirus B19 infection due to lack of virus receptor (erythrocyte P antigen). *N Engl J Med* 1994;330:1192-6.
107. Srivastava A, Bruno E, Briddell R, et al. Parvovirus B19-induced perturbation of human megakaryocytopoiesis in vitro. *Blood* 1990;76:1997-2004.
108. O'Sullivan MG, Anderson DC, Fikes JD, et al. Identification of a novel simian parvovirus in cynomolgus monkeys with severe anemia: a paradigm of human B19 parvovirus infection. *J Clin Invest* 1994;93:1571-6.
109. O'Sullivan MG, Anderson DK, Goodrich JA, et al. Experimental infection of cynomolgus monkeys with simian parvovirus. *J Virol* 1997;71:4517-21.
110. Kurtzman GJ, Platanias L, Lustig L, Frickhofen N, Young NS. Feline parvovirus propagates in cat bone marrow cultures and inhibits hematopoietic colony formation in vitro. *Blood* 1989;74:71-81.
111. Segovia JC, Gallego JM, Bueren JA, Almondal JM. Severe leukopenia and dysregulated erythropoiesis in SCID mice persistently infected with the parvovirus minute virus of mice. *J Virol* 1999;73:1774-84.
112. Kurtzman GJ, Cohen BJ, Field AM, Osseas R, Blaese RM, Young NS. The immune response to B19 parvovirus infection and an antibody defect in persistent viral infection. *J Clin Invest* 1989;84:1114-23.
113. Kajigaya S, Fujii H, Field AM, et al. Self-assembled B19 parvovirus capsids, produced in a baculovirus system, are antigenically and immunogenically similar to native virions. *Proc Natl Acad Sci U S A* 1991;88:4646-50.
114. Ballou WR, Reed JL, Noble W, Young NS, Koenig S. Safety and immunogenicity of a recombinant parvovirus B19 vaccine formulated with MF59C.1. *J Infect Dis* 2003;187:675-8.
115. Bansal GP, Hatfield JA, Dunn FE, et al. Candidate recombinant vaccine for human B19 parvovirus. *J Infect Dis* 1993;167:1034-44.
116. Saikawa T, Anderson S, Momoeda M,

- Kajigaya S, Young NS. Neutralizing linear epitopes of B19 parvovirus cluster in the VP1 unique and VP1-VP2 junction regions. *J Virol* 1993;67:3004-9.
117. Zadori Z, Szelei J, Lacoste MC, et al. A viral phospholipase A2 is required for parvovirus infectivity. *Dev Cell* 2001;1:291-302.
118. Lunardi C, Tiso M, Borgato L, et al. Chronic parvovirus B19 infection induces the production of anti-virus antibodies with autoantigen binding properties. *Eur J Immunol* 1998;28:936-48.
119. Erdman DD. Human parvovirus B19: laboratory diagnosis. In: Anderson LJ, Young NS, eds. *Human parvovirus B19*. Vol. 20 of *Monographs in virology*. Basel, Switzerland: Karger, 1997:93-104.
120. Zerbini M, Gallinella G, Cricca M, Bonvicini F, Musiani M. Diagnostic procedures in B19 infection. *Pathol Biol (Paris)* 2002;50:332-8.
121. Anderson MJ, Jones SE, Minson AC. Diagnosis of human parvovirus infection by dot-blot hybridization using cloned viral DNA. *J Med Virol* 1985;15:163-72.
122. Koch WC, Harger JH, Barnstein B, Adler SP. Serologic and virologic evidence for frequent intrauterine transmission of human parvovirus B19 with a primary maternal infection during pregnancy. *Pediatr Infect Dis J* 1998;17:489-94.
123. Fairley CK, Smoleniec JS, Caul OE, Miller E. Observational study of effect of intrauterine transfusions on outcome of fetal hydrops after parvovirus B19 infection. *Lancet* 1995;346:1335-7.
124. Adibo AO, Campbell WA, Feldman D, et al. Resolution of human parvovirus B19-induced nonimmune hydrops after intrauterine transfusion. *J Ultrasound Med* 1998;17:547-50.
125. Goodear M, Hayward C, Crowther C. Foetal intracardiac transfusion for the treatment of severe anaemia due to human parvovirus B-19 infection. *Australas Radiol* 1998;42:275-7.
126. Miyamura K, Kajigaya S, Momoeda M, Smith-Gill SJ, Young NS. Parvovirus particles as platforms for protein presentation. *Proc Natl Acad Sci U S A* 1994;91:8507-11.

Copyright © 2004 Massachusetts Medical Society.

ELECTRONIC ACCESS TO THE JOURNAL'S CUMULATIVE INDEX

At the Journal's site on the World Wide Web (www.nejm.org), you can search an index of all articles published since January 1975 (abstracts 1975-1992, full text 1993-present). You can search by author, key word, title, type of article, and date. The results will include the citations for the articles plus links to the abstracts of articles published since 1993. For nonsubscribers, time-limited access to single articles and 24-hour site access can also be ordered for a fee through the Internet (www.nejm.org).